

Cervical vs. Lumbar Disc Herniation

Cervical disc herniation typically affects the exiting nerve root

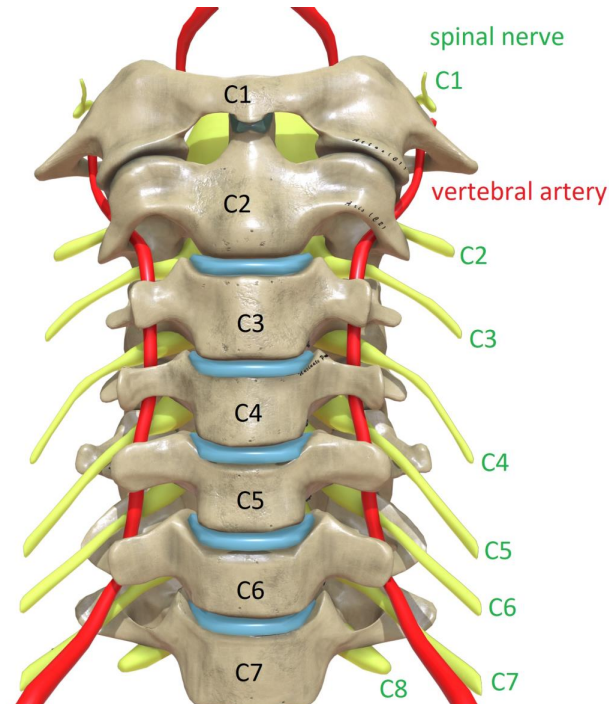
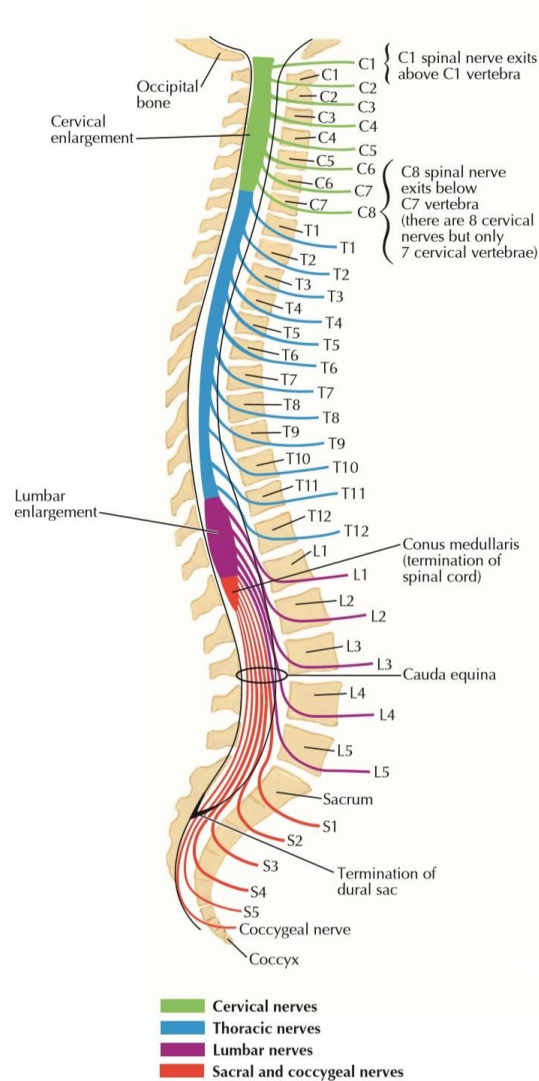


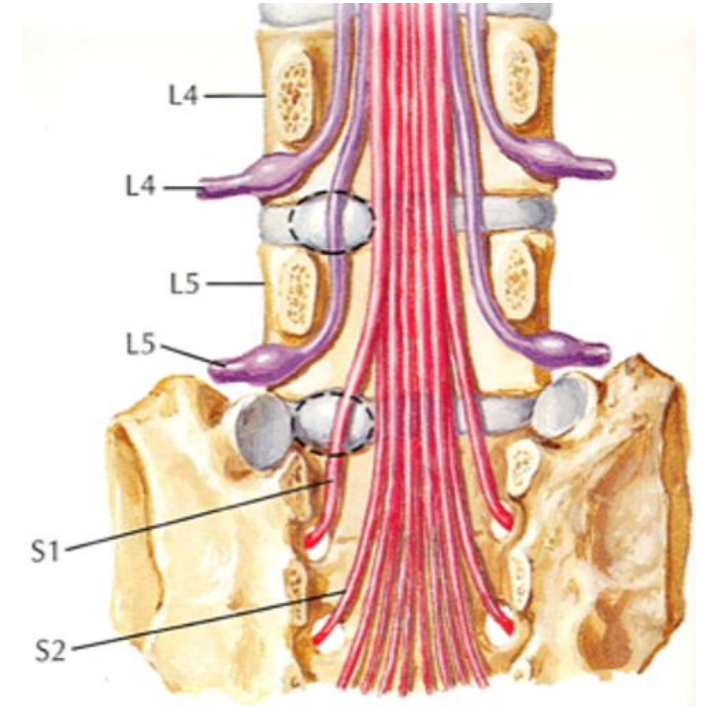
Image modified - from DrJanaOfficial, distributed under a [CC BY-SA 4.0](https://creativecommons.org/licenses/by-sa/4.0/) licence.

- ex. C5/6 disc herniation affects C6 nerve root



- ex. L4/5 disc herniation affects the L5 nerve root

Lumbar disc herniation typically affects the traversing nerve root



In both cases, the spinal nerve typically affected by a disc herniation has the same number as the inferior vertebral level of the disc.