

The Return of Phineas Gage: Clues About the Brain from The Skull of a Famous Patient



Hanna Damasio; Thomas Grabowski; Randall Frank; Albert M. Galaburda; Antonio R. Damasio

Science, New Series, Vol. 264, No. 5162 (May 20, 1994), 1102-1105.

Stable URL:

<http://links.jstor.org/sici?sici=0036-8075%2819940520%293%3A264%3A5162%3C1102%3ATROPGC%3E2.0.CO%3B2-Q>

Science is currently published by American Association for the Advancement of Science.

Your use of the JSTOR archive indicates your acceptance of JSTOR's Terms and Conditions of Use, available at <http://www.jstor.org/about/terms.html>. JSTOR's Terms and Conditions of Use provides, in part, that unless you have obtained prior permission, you may not download an entire issue of a journal or multiple copies of articles, and you may use content in the JSTOR archive only for your personal, non-commercial use.

Please contact the publisher regarding any further use of this work. Publisher contact information may be obtained at <http://www.jstor.org/journals/aaas.html>.

Each copy of any part of a JSTOR transmission must contain the same copyright notice that appears on the screen or printed page of such transmission.

JSTOR is an independent not-for-profit organization dedicated to creating and preserving a digital archive of scholarly journals. For more information regarding JSTOR, please contact support@jstor.org.

The Return of Phineas Gage: Clues About the Brain from the Skull of a Famous Patient

Hanna Damasio, Thomas Grabowski, Randall Frank,
Albert M. Galaburda, Antonio R. Damasio*

When the landmark patient Phineas Gage died in 1861, no autopsy was performed, but his skull was later recovered. The brain lesion that caused the profound personality changes for which his case became famous has been presumed to have involved the left frontal region, but questions have been raised about the involvement of other regions and about the exact placement of the lesion within the vast frontal territory. Measurements from Gage's skull and modern neuroimaging techniques were used to reconstitute the accident and determine the probable location of the lesion. The damage involved both left and right prefrontal cortices in a pattern that, as confirmed by Gage's modern counterparts, causes a defect in rational decision making and the processing of emotion.

On 13 September 1848, Phineas P. Gage, a 25-year-old construction foreman for the Rutland and Burlington Railroad in New England, became a victim of a bizarre accident. In order to lay new rail tracks across Vermont, it was necessary to level the uneven terrain by controlled blasting. Among other tasks, Gage was in charge of the detonations, which involved drilling holes in the stone, partially filling the holes with explosive powder, covering the powder with sand, and using a fuse and a tamping iron to trigger an explosion into the rock. On the fateful day, a momentary distraction let Gage begin tamping directly over the powder before his assistant had had a chance to cover it with sand. The result was a powerful explosion away from the rock and toward Gage. The fine-pointed, 3-cm-thick, 109-cm-long tamping iron was hurled, rock-et-like, through his face, skull, brain, and then into the sky. Gage was momentarily stunned but regained full consciousness immediately thereafter. He was able to talk and even walk with the help of his men. The iron landed many yards away (1).

Phineas Gage not only survived the momentous injury, in itself enough to earn him a place in the annals of medicine, but he survived as a different man, and therein lies the greater significance of this case. Gage had been a responsible, intelligent, and socially well-adapted individual, a favorite with peers and elders. He had made progress and showed promise. The signs of a

profound change in personality were already evident during the convalescence under the care of his physician, John Harlow. But as the months passed it became apparent that the transformation was not only radical but difficult to comprehend. In some respects, Gage was fully recovered. He remained as able-bodied and appeared to be as intelligent as before the accident; he had no impairment of movement or speech; new learning was intact, and neither memory nor intelligence in the conventional sense had been affected. On the other hand, he had become irreverent and capricious. His respect for the social conventions by which he once abided had vanished. His abundant profanity offended those around him. Perhaps most troubling, he had taken leave of his sense of responsibility. He could not be trusted to honor his commitments. His employers had deemed him "the most efficient and capable" man in their "employ" but now had to dismiss him. In the words of his physician, "the equilibrium or balance, so to speak, between his intellectual faculty and animal propensities" had been destroyed. In the words of his friends and acquaintances, "Gage was no longer Gage" (1). Gage began a new life of wandering that ended a dozen years later, in San Francisco, under the custody of his family. Gage never returned to a fully independent existence, never again held a job comparable to the one he once had. His accident had made headlines but his death went unnoticed. No autopsy was obtained.

Twenty years after the accident, John Harlow, unaided by the tools of experimental neuropsychology available today, perceptively correlated Gage's cognitive and behavioral changes with a presumed area of focal damage in the frontal region (1). Other cases of neurological damage were then revealing the brain's foundation for

language, motor function, and perception, and now Gage's case indicated something even more surprising: Perhaps there were structures in the human brain dedicated to the planning and execution of personally and socially suitable behavior, to the aspect of reasoning known as rationality.

Given the power of this insight, Harlow's observation should have made the scientific impact that the comparable suggestions based on the patients of Broca and Wernicke made (2). The suggestions, although surrounded by controversy, became the foundation for the understanding of the neural basis of language and were pursued actively, while Harlow's report on Gage did not inspire a search for the neural basis of reasoning, decision-making, or social behavior. One factor likely to have contributed to the indifferent reception accorded Harlow's work was that the intellectual atmosphere of the time made it somewhat

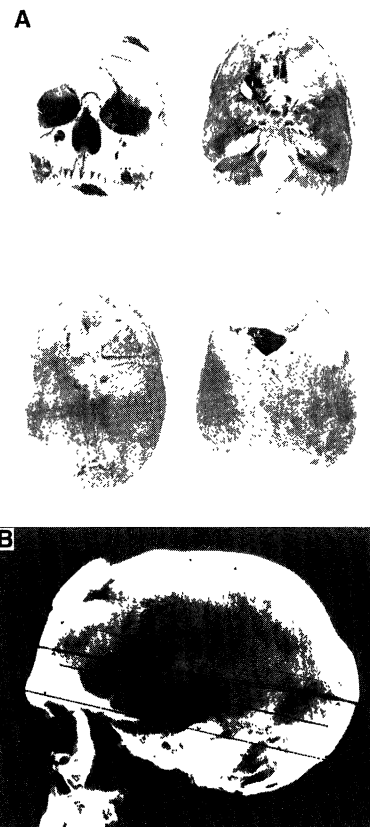


Fig. 1. Photographs of (A) several views of the skull of Phineas Gage and (B) the skull x-ray.

H. Damasio and A. R. Damasio are in the Department of Neurology, University of Iowa Hospitals & Clinics, Iowa City, IA 52242, and the Salk Institute for Biological Research, San Diego, CA 92186-5800, USA. T. Grabowski and R. Frank are in the Department of Neurology, University of Iowa Hospitals & Clinics, Iowa City, IA 52242, USA. A. M. Galaburda is in the Department of Neurology, Harvard Medical School, Beth Israel Hospital, Boston, MA 02215, USA.

*To whom correspondence should be addressed.

more acceptable that there was a neural basis for processes such as movement or even language rather than for moral reasoning and social behavior (3). But the principal explanation must rest with the substance of Harlow's report. Broca and Wernicke had autopsy results, Harlow did not. Unsupported by anatomical evidence, Harlow's observation was the more easily dismissed. Because the exact position of the lesion was not known, some critics could claim that the damage actually involved Broca's so-called language "center," and perhaps would also have involved the nearby "motor centers." And because the patient showed neither paralysis nor aphasia, some critics reached the conclusion that there were no specialized regions at all (4). The British physiologist David Ferrier was a rare dissenting voice. He thoughtfully ventured, in 1878, that the lesion spared both motor and language centers, that it had damaged the left prefrontal cortex, and that such damage probably explained Gage's behavioral defects, which he aptly described as a "mental degradation" (5).

Harlow only learned of Gage's death about 5 years after its occurrence. He proceeded to ask Gage's family to have the body exhumed so that the skull could be recovered and kept as a medical record. The strange request was granted, and Phineas

Gage was once again the protagonist of a grim event. As a result, the skull and the tamping iron, alongside which Gage had been buried, have been part of the Warren Anatomical Medical Museum at Harvard University.

As new cases of frontal damage were described in this century, some of which did resemble that of Gage, and as the enigmas of frontal lobe function continued to resist elucidation, Gage gradually acquired landmark status. Our own interest in the case grew out of the idea that Gage exemplified a particular type of cognitive and behavioral defect caused by damage to ventral and medial sectors of prefrontal cortex, rather than to the left dorsolateral sector as implicit in the traditional view. It then occurred to us that some of the image processing techniques now used to investigate Gage's counterparts could be used to test this idea by going back in time, reconstituting the accident, and determining the probable placement of his lesion. The following is the result of our neuroanthropological effort.

We began by having one of us (A.M.G.) photograph Gage's skull inside and out and obtain a skull x-ray (Fig. 1) as well as a set of precise measurements (6) relative to bone landmarks. Using these measurements, we proceeded to deform linearly the three-dimensional

reconstruction of a standard human skull (7) so that its dimensions matched those of Phineas Gage's skull. We also constructed Talairach's stereotactic space for both this skull and Phineas Gage's real skull (8). On the basis of the skull photographs, the dimensions of the entry and exit holes were scaled and mapped into the deformed standard skull. Based on measurements of the iron rod and on the recorded descriptions of the accident, we determined the range of likely trajectories of the rod. Finally, we simulated those trajectories in three-dimensional space using Brainvox (9). We modeled the rod's trajectory as a straight line connecting the center of the entry hole at orbital level to the center of the exit hole. This line was then carried downward to the level of the mandibular ramus. The skull anatomy allowed us to consider entry points within a 1.5-cm radius of this point (20 points in all) (Fig. 2).

Possible exit points were determined as follows: We decided to constrain the exit point to be at least 1.5 cm (half the diameter of the rod) from the lateral and posterior margins of the area of bone loss (Fig. 3) because there were no disruptions of the outer table of the calvarium in these directions (Fig. 1, lower right panel). However, we accepted that the rod might have passed up to 1.5 cm anterior to the area of bone loss because inspection of the bone in this region revealed that it must have been separated completely from the rest of the calvarium (Fig. 1). Furthermore, the wound was described as an inverted funnel (1). We tested 16 points within the rectangular-shaped area that we constructed (Fig. 3).

The trajectory connecting each of the entry and exit points was tested at multiple anatomical levels. The three-dimensional skull was resampled in planes perpendicular to the best a priori trajectory (C in Figs. 2 and 3). We were helped by several important anatomical constraints. We knew that the left mandible was intact; that the zygomatic arch was mostly intact but had a chipped area, at its medial and superior edge, that suggested the rod had grazed it; and that the last superior molar socket was intact although the tooth was missing. Acceptable trajectories were those which, at each level, did not violate the following rules: The vectors representing the trajectories could not be closer than 1.5 cm from the mid-thickness of the zygomatic arch, 1 cm from the last superior molar, and 0.5 cm from the coronoid process of the mandible (10). Only seven trajectories satisfied these conditions (Fig. 4). Two of those seven invariably hit the anterior horn of the lateral ventricle and were therefore rejected as anatomically improbable because they would not have been compatible with survival (the resulting massive infection would not have

Fig. 2. View of the entry-level area with the a priori most likely first trajectory. (A) Skull with this first vector and the level (red) at which entry points were marked. (B) View of a segment of section 1. On the left is the mandibular ramus, and on the right is the array of entry points. (C) Enlargement of the array of entry points. One additional point was added (L20) to ensure that every viable entry point was surrounded by nonviable points. Nonviable vectors are shown in red and viable vectors with labels identifying their exit points are shown in green. Abbreviations: A, anterior; L, lateral; P, posterior; AM, anteromesial; AL, anterolateral; PL, posterolateral; C, central.

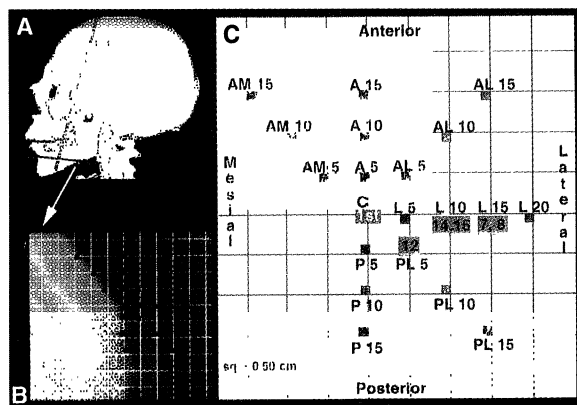


Fig. 3. (A) View from above of the deformed skull with the exit hole and the anterior bone flap traced in black. The blue circle represents the first vector tested, and the gray surface represents the area where exit points were tested. (B) Schematic enlargement of the exit hole and of the area tested for exit points. The letter C marks the first tested vector (blue). The numbers 1 through 15 mark the other exit points tested. Red indicates nonviable vectors, green indicates viable vectors, and the label identifies the entry point. Note that the a priori best fit C was not viable.

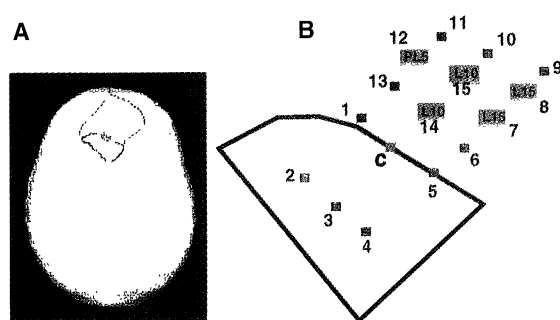
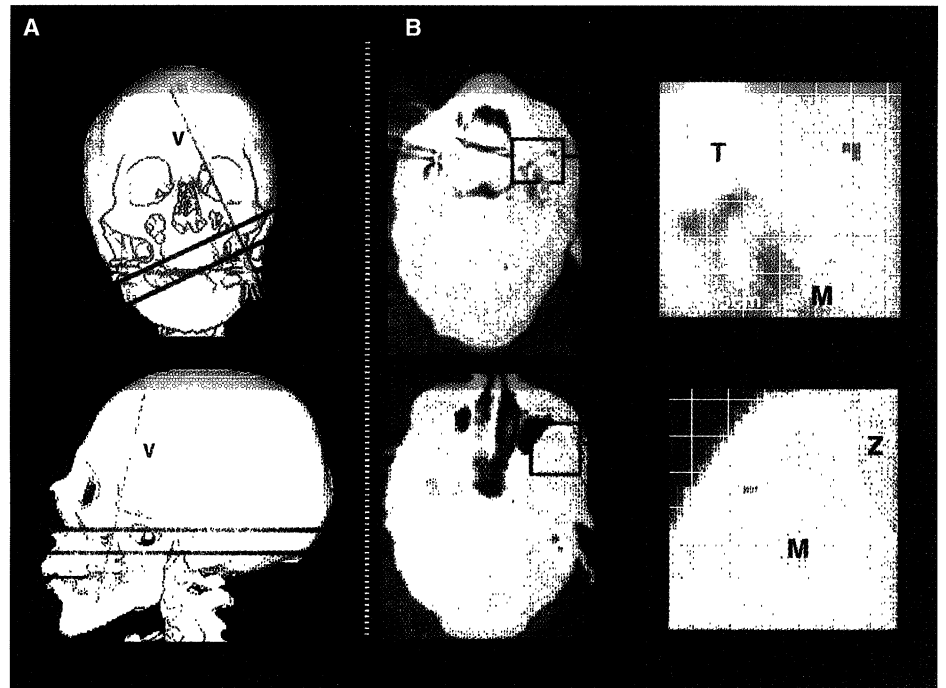


Fig. 4. (A) Front and lateral skull views with the projection of the five final vectors (V). The two red lines show the position of the two sections seen in (B). (B) Skull sections 2 and 3: examples of two bottleneck levels at which the viability of vectors was checked. Next to each section is an enlargement of the critical area. Abbreviations: T, missing tooth; M, intact mandible; Z, intact zygoma with a chipped area (light blue).



been controllable in the preantibiotic era). When checked in our collection of normal brains, one of the remaining five trajectories behaved better than any other relative to the lower constraints and was thus chosen as the most likely trajectory. The final step was to model the five acceptable trajectories of the iron rod in a three-dimensional reconstruction of a human brain that closely fit Phineas Gage's assumed brain dimensions (11). Talairach's stereotactic warpings were used for this final step.

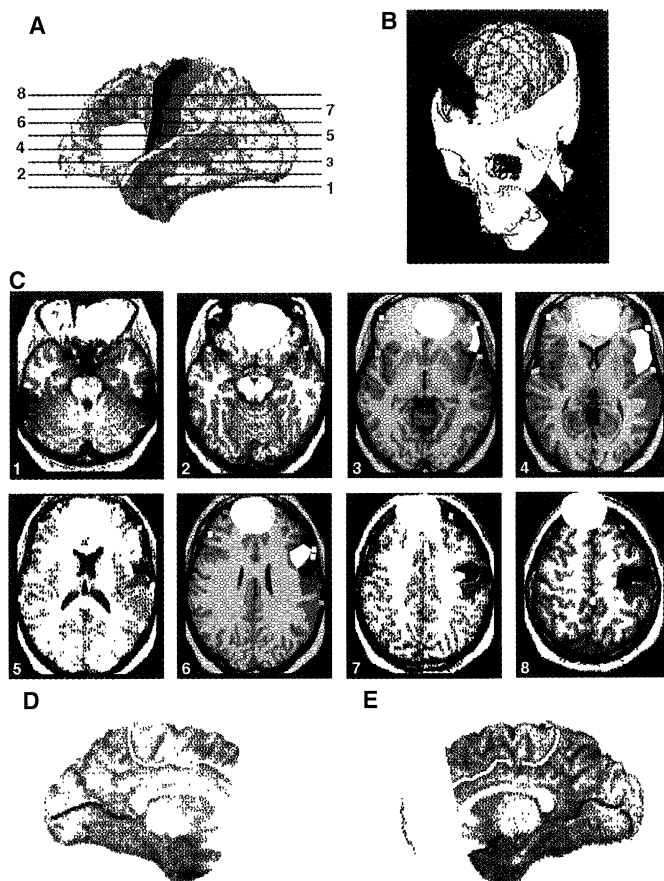
The modeling yielded the results shown in Fig. 5. In the left hemisphere, the lesion involved the anterior half of the orbital frontal cortex (Brodmann's cytoarchitectonic fields 11 and 12), the polar and anterior mesial frontal cortices (fields 8 to 10 and 32), and the anterior-most sector of the anterior cingulate gyrus (field 24). However, the lesion did not involve the mesial aspect of field 6 [the supplementary motor area (SMA)].

The frontal operculum, which contains Broca's area and includes fields 44, 45, and 47, was also spared, both cortically and in the underlying white matter. In the right hemisphere, the lesion involved part of the ante-

rior and mesial orbital region (field 12), the mesial and polar frontal cortices (fields 8 to 10 and 32), and the anterior segment of the anterior cingulate gyrus (field 24). The SMA was spared. The white matter core of the frontal lobes was more extensively damaged in the left hemisphere than in the right. There was no damage outside of the frontal lobes.

Even allowing for error and taking into consideration that additional white matter damage likely occurred in the surround of the iron's trajectory, we can conclude that the lesion did not involve Broca's area or the motor cortices and that it favored the ventromedial region of both frontal lobes while sparing the dorsolateral. Thus, Ferrier was correct, and Gage fits a neuroanatomical pattern that we have identified to date in 12 patients within a group of 28 individuals with frontal damage (12). Their ability to make rational decisions in personal and social matters is invariably compromised and so is their processing of emotion. On the contrary, their ability to tackle the logic of an abstract problem, to perform calculations, and to call up appropriate knowledge and attend to it remains intact. The establishment of such a pattern has led to the hypothesis that emotion and its underlying neural machinery participate in decision making within the social domain and has raised the possibility that the participation depends on the ventromedial frontal region (13). This region is reciprocally connected with subcortical nuclei that control basic biological regulation, emotional processing, and social cognition and behavior, for instance, in amygdala and hypothalamus (14). Moreover, this region shows a high concen-

Fig. 5. Normal brain fitted with the five possible rods. The best rod is highlighted in solid white [except for (B), where it is shown in red]. The areas spared by the iron are highlighted in color: Broca, yellow; motor, red; somatosensory, green; Wernicke, blue. (A) Lateral view of the brain. Numbered black lines correspond to levels of the brain section shown in (C). (D and E) Medical view of left and right hemispheres, respectively, with the rod shown in white.



tration of serotonin S_2 receptors in monkeys whose behavior is socially adapted as well as a low concentration in aggressive, socially uncooperative animals (15). In contrast, structures in the dorsolateral region are involved in other domains of cognition concerning extrapersonal space, objects, language, and arithmetic (16). These structures are largely intact in Gage-like patients, thus accounting for the patients' normal performance in traditional neuropsychologic tests that are aimed at such domains.

The assignment of frontal regions to different cognitive domains is compatible with the idea that frontal neurons in any of those regions may be involved with attention, working memory, and the categorization of contingent relationships regardless of the domain (17). This assignment also agrees with the idea that in non-brain-damaged individuals the separate frontal regions are interconnected and act cooperatively to support reasoning and decision making. The mysteries of frontal lobe function are slowly being solved, and it is only fair to establish, on a more substantial footing, the roles that Gage and Harlow played in the solution.

REFERENCES AND NOTES

- J. M. Harlow, *Pub. Mass. Med. Soc.* **2**, 327 (1868).
- P. Broca, *Bull. Soc. Anthropol.* **6**, 337 (1865); C. Wernicke, *Der aphasische Symptomencomplex* (Cohn and Weigert, Breslau, Poland, 1874). A remarkable number of basic insights on the functional specialization of the human brain, from motor function to sensory perception and to spoken and written language, came from the description of such cases mostly during the second half of the 19th century. The cases usually acted as a springboard for further research, but on occasion their significance was overlooked, as in the case of Gage. Another such example is the description of color perception impairment (achromatopsia) caused by a ventral occipital lesion, by D. Verrey [*Arch. Ophthalmol. (Paris)* **8**, 289 (1888)]. His astonishing finding was first denied and then ignored until the 1970s.
- Reasoning and social behavior were deemed inextricable from ethics and religion and not amenable to biological explanation.
- The reaction against claims for brain specialization was in fact a reaction against phrenological doctrines, the curious and often unacknowledged inspiration for many of the early case reports. The views of E. Dupuy exemplify the attitude [*Examen de Quelques Points de la Physiologie du Cerveau* (Delahaye, Paris, 1873); M. MacMillan, *Brain Cognit.* **5**, 67 (1986)].
- D. Ferrier, *Br. Med. J.* **1**, 399 (1878).
- The first measurements were those necessary to construct Gage's Talairach stereotactic space and deform a three-dimensional, computerized tomography skull: the maximum length of the skull, the maximum height of the skull above the inion-glabella line, the distance from this line to the floor of the middle fossa, the maximum width of the skull, and the position of the section contour of Gage's skull relative to the inion-glabella line. The second measurements were those necessary to construct the entry and exit areas: on the top external view, the measure of edges of the triangular exit hole; on the internal view the distances from its three corners to the mid-sagittal line and to the nasion; the distance from the borders of the hole to the fracture lines seen anteriorly and posteriorly to this hole; and the dimensions of the entry hole at the level of the orbit.
- Thin-cut standard computerized tomography image of a cadaver head obtained at North Carolina Memorial Hospital.
- We introduced the following changes to the method described by P. Fox, J. Perlmutter, and M. Raichle [*J. Comput. Assist. Tomogr.* **9**, 141 (1985)]. We calculated the mean distance from the anterior commissure (AC) to the posterior commissure (PC) in a group of 27 normal brains and used that distance for Gage (26.0 mm). We also did not consider the AC-frontal pole and the PC-occipital pole distances as equal because our group of normals had a mean difference of 5 mm between the two measures, and Talairach himself did not give these two measurements as equal [J. Talairach and G. Szikla, *Atlas d'Anatomie Stereotaxique du Telencephale* (Masson, Paris, 1967); J. Talairach and P. Tournoux, *Coplanar Stereotaxic Atlas of the Human Brain* (Thieme, New York, 1988)]. We introduced an anterior shift of 3% to the center of the AC-PC line and used that point as the center of the AC-PC segment. This shift meant that the anterior sector of Talairach's space was 47% of the total length and that the posterior was 53%. We had no means of calculating the difference between the right and left width of Gage's brain; therefore, we assumed them to be equal.
- H. Damasio and R. Frank, *Arch. Neurol.* **49**, 137 (1992).
- There were two reasons to allow the vector this close to the mandible: (i) The zygomatic arch and the coronoid process were never more than 2 cm apart; (ii) we assumed that, in reality, this distance might have been larger if the mouth were open or if the mandible, a movable structure, had been pushed by the impact of the iron rod.
- The final dimensions of Phineas Gage's Talairach space were as follows: total length, 171.6 mm; total height, 111.1 mm; and total width, 126.5 mm. Comparing these dimensions to a group of 27 normal subjects, we found that in seven cases at least two of the dimensions were close to those of Phineas Gage [mean length, 169.9 mm (SD, 4.1); mean height, 113.6 (SD, 2.3), mean width, 125 (SD, 3.9)]. The seven brains were fitted with the possible trajectories to determine which brain areas were involved. There were no significant differences in the areas of damage. The modeling we present here was performed on subject 1600LL (length, 169 mm; height, 115.2 mm; width, 125.6 mm).
- Data from the Lesion Registry of the University of Iowa's Division of Cognitive Neuroscience as of 1993.
- P. Eslinger and A. R. Damasio, *Neurology* **35**, 1731 (1985); J. L. Saver and A. R. Damasio, *Neuropsychologia* **29**, 1241 (1991); A. R. Damasio, D. Tranel, H. Damasio, in *Frontal Lobe Function and Dysfunction*, H. S. Levin, H. M. Eisenberg, A. L. Benton, Eds. (Oxford Univ. Press, New York, 1991), pp. 217–229; S. Dehaene and J. P. Changeux, *Cereb. Cortex* **1**, 62 (1991).
- P. S. Goldman-Rakic, in *Handbook of Physiology: The Nervous System*, F. Plum, Ed. (American Physiological Society, Bethesda, MD, 1987), vol. 5, pp. 373–401; D. N. Pandya and E. H. Yeterian, in *The Prefrontal Cortex: Its Structure, Function and Pathology*, H. B. M. Uylings, Ed. (Elsevier, Amsterdam, 1990); H. Barbas and D. N. Pandya, *J. Comp. Neurol.* **286**, 253 (1989).
- M. J. Raleigh and G. L. Brammer, *Soc. Neurosci. Abstr.* **19**, 592 (1993).
- M. Petrides and B. Milner, *Neuropsychologia* **20**, 249 (1982); J. M. Fuster, *The Prefrontal Cortex* (Raven, New York, ed. 2, 1989); M. I. Posner and S. E. Petersen, *Annu. Rev. Neurosci.* **13**, 25 (1990).
- P. S. Goldman-Rakic, *Sci. Am.* **267**, 110 (September 1992); A. Bechara, A. R. Damasio, H. Damasio, S. Anderson, *Cognition* **50**, 7 (1994); A. R. Damasio, *Descartes' Error: Emotion, Reason and the Human Brain* (Putnam, New York, in press).
- We thank A. Paul of the Warren Anatomical Museum for giving us access to Gage's skull. Supported by National Institute of Neurological Diseases and Stroke grant PO1 NS19632 and by the Mathers Foundation.

RESEARCH ARTICLE

Highly Conjugated, Acetylenyl Bridged Porphyrins: New Models for Light-Harvesting Antenna Systems

Victor S.-Y. Lin, Stephen G. DiMugno, Michael J. Therien*

A new class of porphyrin-based chromophore systems has been prepared from ethyne-elaborated porphyrin synthons through the use of metal-mediated cross-coupling methodologies. These systems feature porphyrin chromophores wired together through single ethynyl linkages. This type of topological connectivity affords exceptional electronic interactions between the chromophores which are manifest in their room temperature photophysics, optical spectroscopy, and electrochemistry; these spectroscopic signatures indicate that these species model many of the essential characteristics of biological light-harvesting antenna systems.

The optical, electronic, and photophysical properties of porphyrins have made these molecules desirable targets for incorporation into supramolecular systems and polymers due to their central importance in

the developing biomimetic chemistry of multichromophoric assemblies in biology as well as for potential application in sensing (1), opto-electronic (2), magnetic (3), artificial photosynthetic (4, 5), catalytic (6),